

Scientific Evidence Supporting fasciotens®

Stay informed about innovative approaches that enhance surgical success and patient recovery, supported by data from your colleagues' clinical experience. This handout provides concise summaries of peer-reviewed publications on fasciotens® authored by respected experts in the field. These studies highlight:

- Clinical evidence supporting the safety and efficacy of fasciotens® devices
- Real-world data on their integration into surgical practice
- The expanding adoption of vertical fascial traction within the global AWR community

Access the Full Collection:

Scan the QR code or visit

www.fasciotens.com/downloads#publication

to explore all publications on fasciotens® and its role in advancing abdominal wall surgery



Discuss your case with our surgical experts:

Book a meeting with one of our surgeons and discuss your case of complex abdominal wall hernias, open abdomen or pediatric abdominal wall defects.

Scan the QR code or visit

www.fasciotens.com/case-discussion



fasciotens® Hernia

Hernia (2024)

Preoperative botulinum toxin A (BTA) and intraoperative fascial traction (IFT) in the management of complex abdominal wall hernias

Niebuhr, H., Wegner, F., Dag, H. et al.

The study provides an overview of using IFT and BTA in complex hernia surgery and assesses short-term outcomes (after 30 days). Cases were included if BTA and Rives-Stoppa alone did not lead to a reconstruction of the abdominal wall. Intraoperative reduction of transverse hernia diameter of 9.81 cm (mean) is in line with findings from previous studies. The **Hamburg algorithm** was developed based on the results.

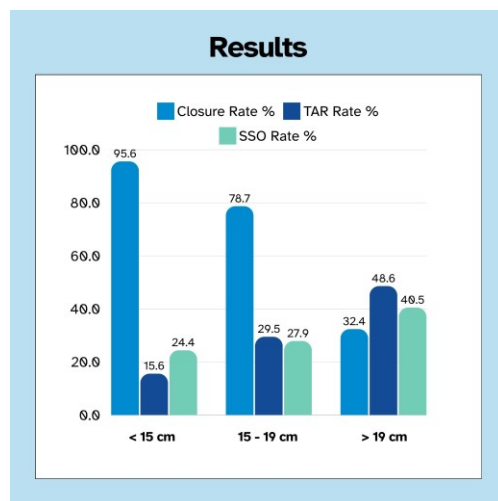


Figure is part of publication

- ✓ Closure rate of 95.6 % in cases up to 15 cm width
- ✓ Mean operative time of 183.6 min including 30 min of IFT (less than comparable data for TAR - Novitsky Y. W. et al, Ann Surg. 2016)
- ✓ TAR rate increases with hernia diameter
- ✓ Complication and re-operation rates are significantly higher if additional TAR was performed (see graph for details)

Chirurg 93, 292-298 (2022)

Intraoperative fascial traction (IFT) for the treatment of large ventral hernias

Niebuhr, H., Malaibari, Z.O., Köckerling, F. et al.

This study summarizes a retrospective analysis of 50 cases treated with IFT. 94 % of the patients had a hernia width above 10 cm (W3 according to EHS). Mean defect size before traction was measured at 16.1 cm intraoperatively.

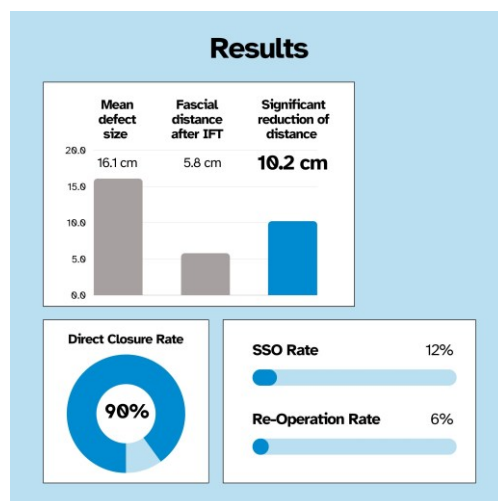


Figure created by fasciotens

- ✓ 90% successful closure
- ✓ Low complication rate: 12% postoperative complications whereof 50% didn't need surgical intervention
- ✓ All patients received augmentation in sublay position
- ✓ No cases of abdominal compartment syndrome

Journal of Abdominal Wall Surgery, 1:10356 (2022)

Intraoperative Fascial Traction in Robotic Abdominal Wall Surgery; An Early Experience

A. L. A. Bloemendaal

The first article reporting three cases combining robotic ventral hernia repair and intraoperative fascial traction (IFT). A retromuscular hernia repair was performed followed by a transcutaneous IFT.

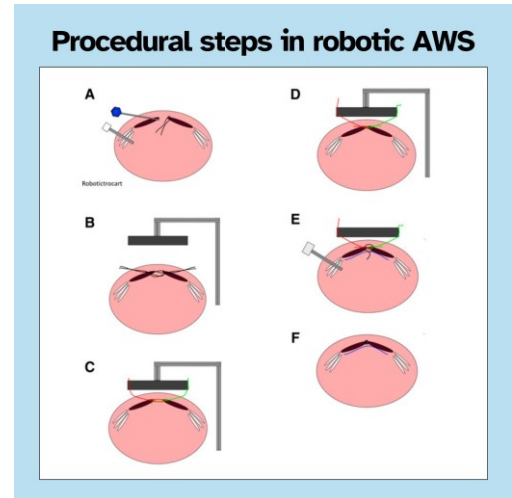


Figure created by fasciotens with images from publication

- ✓ **First cases showed promising results**
- ✓ **IFT facilitates robotic suturing of the hernia defect**
- ✓ **IFT is easily combinable with robotic hernia repair**
- ✓ **IFT can potentially be used in robotic repair for very large defects**

Hernia (2024 April 14)

Assessment of myofascial medialization following intraoperative fascial traction (IFT) in a cadaveric model

Niebuhr H, Reinbold W, Morgenroth F, Berger C, Dag H, Wehrenberg U, Trzewik J, Köckerling F

This study provides controlled, comparable data on the impact of IFT on the abdominal wall, aligning with similar studies for component separation.

Procedure:

- ✓ Retromuscular dissection (Rives-Stoppa) performed on 4 fresh-frozen specimens
- ✓ Followed by 30 minutes of fascial traction using fasciotens®Hernia
- ✓ Medial advancement of the lateral abdominal wall measured after 15 and 30 minutes
- ✓ Total medialization of 10.5 cm (mean) after 30 minutes with mean traction forces of 16.28 kg

In summary, the study confirms the results from the intraoperative use of fasciotens®Hernia.

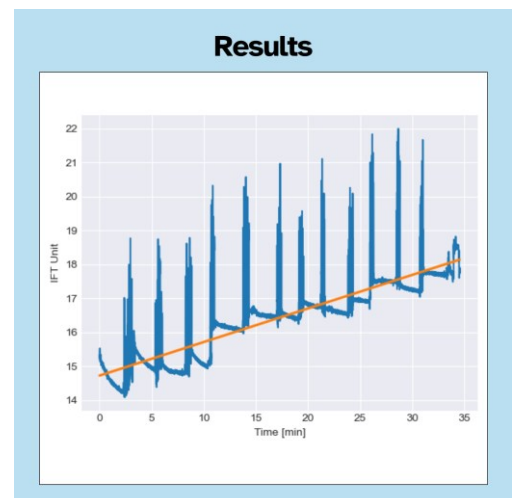


Figure created by fasciotens, graph from publication

fasciotens® Abdomen

Front. Surg. 11:1449702 (2024)

Evaluating a novel vertical traction device for early closure in open abdomen management: a consecutive case series

Dohmen J, Weissinger D, Peter AST, Theodorou A, Kalff JC, Stoffels B, Lingohr P, von Websky M.

This study is the first to examine the effect of the application of fasciotens® Abdomen on intra-abdominal pressure (IAP). The study concludes that fasciotens® Abdomen is a safe and feasible option for managing OA cases. By promoting early definitive fascial closure, fasciotens® Abdomen may help reduce complications associated with OA.

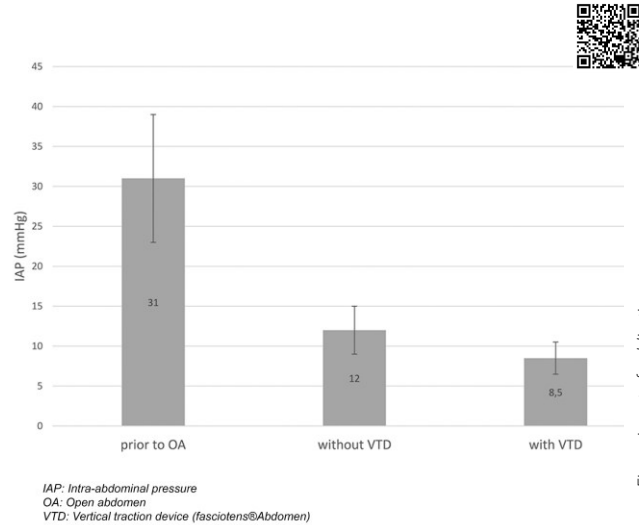


Figure is part of publication

- ✓ **Reduction of IAP from 31 ± 8 mmHg (before OA) to 8.5 ± 2 mmHg after fasciotens application**
- ✓ **Average of 3 ± 1 revisional surgeries**
- ✓ **Reduction in the fascia-to-fascia distance by 76% until definitive fascial closure**
- ✓ **Definitive fascial closure in 6/9 patients**

Surgical Technology Int. 44th Edition (2024)

Vertical Mesh-Mediated Fascial Traction and Negative Pressure Wound Therapy: A Case Series of Nine Patients in General and Vascular Surgery

Thomas Mones et al.

This publication shows the positive outcomes of the standardized combination of vertical mesh-mediated fascial traction (VMMFT) and negative pressure wound therapy (NPWT) while following a strict treatment pathway. Additionally, it describes the VAC draping technique.

Algorithm for VMMFT using a device to apply controlled and reproducible traction to the abdominal wall (fasciotens® Abdomen) in combination with NPWT:

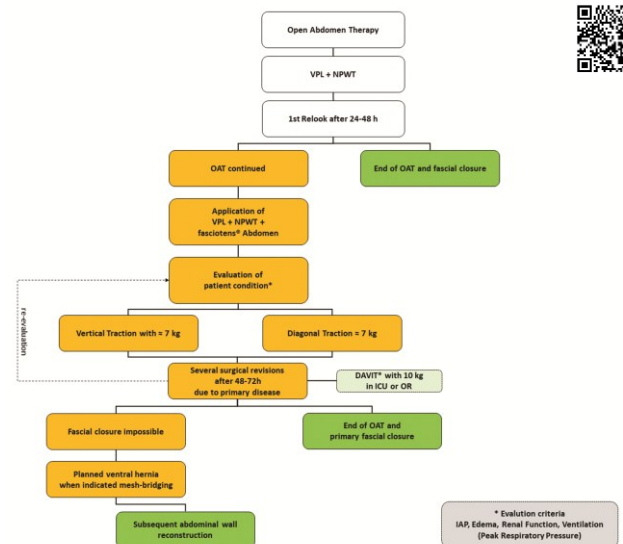


Figure is part of publication

- ✓ **Treatment algorithm for VMMFT in combination with NPWT**
- ✓ **Mean closure time of 6.2 days**
- ✓ **Definitive fascial closure in 7/9 patients (initial mean fascial dehiscence 14.2 cm)**
- ✓ **No treatment-related complications**

Surgery Surg Endos 2023; 5(1) Suppl. 2: 62-67

Fasciotens® Abdomen system application for delayed primary fascial closure and observed physiological improvement of the patient

Mavc, Z., Kunst, G.

fasciotens® Abdomen was used in a middle-aged patient with severe peritonitis after small bowel perforation.

"Post-installation of the device, rapid improvements in respiratory dynamics, diuresis, stoma output, and hemodynamics were observed within hours, suggesting a profound impact on overall well-being. This cascade of physiological benefits hints at broader implications in optimizing patient recovery."

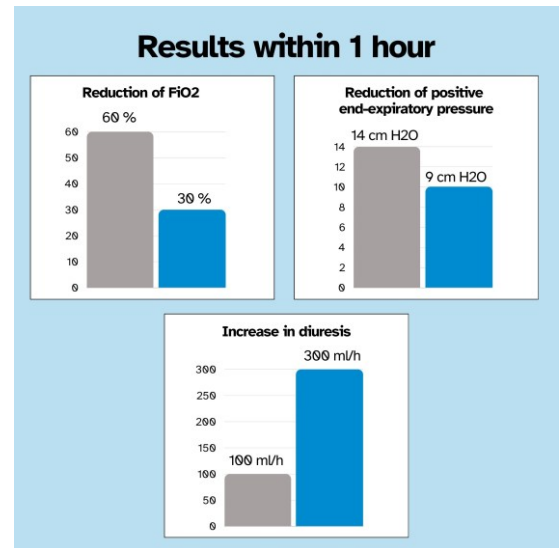


Figure created by fasciotens

- ✓ Overall stabilization of the patient
- ✓ Successful fascial closure after 6 days of using fasciotens

- ✓ Increased renal output
- ✓ Improvement of ventilation parameters

Langenbecks Arch Surg 407, 2075-2083 (2022)

Vertical traction device prevents abdominal wall retraction and facilitates early primary fascial closure of septic and non-septic open abdomen

Fung, S., Ashmawy, H., Krieglstein, C. et al.

First retrospective multicenter study on fasciotens® Abdomen showing promising results and demonstrates safety and feasibility of the device.

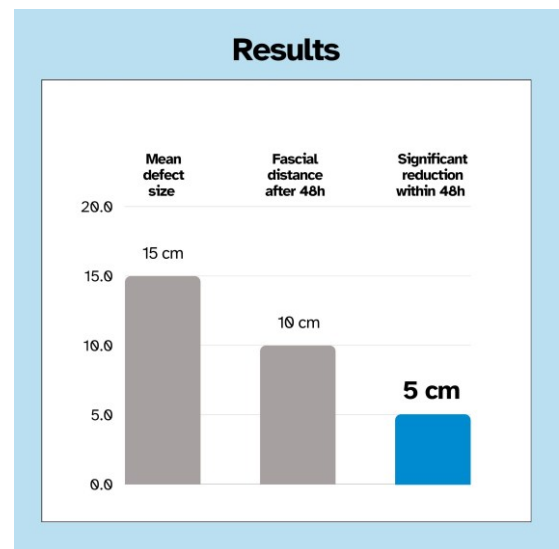


Figure created by fasciotens

- ✓ 100% successful early closure
- ✓ After 48h: Fascial distance significantly reduced

- ✓ Mean of 7 days for definitive fascial closure
- ✓ Initial mean fascial dehiscence 15 cm

fasciotens® Pediatric

Pediatric Surgery International 40, 172 (2024)

Use of a new vertical traction device for early traction-assisted staged closure of congenital abdominal wall defects: a prospective series of 16 patients

Ziegler, AM., Svoboda, D., Lüken-Darius, B. et al.

First multi-center study to explore feasibility and safety of fasciotens® Pediatric device in giant Omphaloceles (GOC) and complex Gastroschisis (GS). The authors conclude that the device enabled an early tension-free closure of the defects.

Day 3 of traction

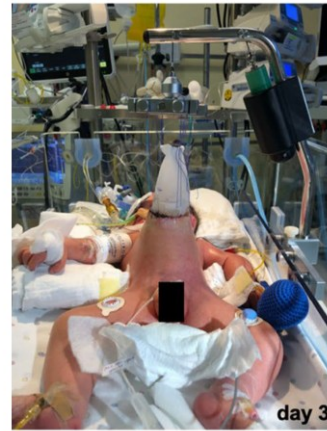

Figure created by fasciotens, picture from publication

- ✓ Traction forces btw. 500g - 1.000g (<50% of the patient's weight) applied
- ✓ Definitive abdominal wall closure after a median time of 7 days (GOC) / 5 days (GS)
- ✓ No hernia formation after mean follow-up of 12 months
- ✓ No device-related adverse events

Publications about fasciotens®

HERNIA

Niebuhr, H., Wegner, F., Dag, H. et al., 2024: **Preoperative botulinum toxin A (BTA) and intraoperative fascial traction (IFT) in the management of complex abdominal wall hernias**

Niebuhr et. al., 2024: **Assessment of myofascial medialization following intraoperative fascial traction (IFT) in a cadaveric model**

D. Eucker, R. Rosenberg, 2023: **„Loss of domain“ und Verringerung der medianen Nahtspannung**

J. Gorjanc et. al., 2023: **The use of intraoperative fascial traction in W3-incisional hernia repair: A revolution or an emergency exit (two case reports)**

Niebuhr, H., Malaibari, Z.O., Köckerling, F. et al., 2022: **Intraoperative fascial traction (IFT) for the treatment of large ventral hernias**

A. L. A. Bloemendaal, 2022: **Intraoperative Fascial Traction in Robotic Abdominal Wall Surgery; An Early Experience**

B. Romain, G. Sauvineta, T. Rebierea, 2022: **A complex incisional hernia repair with Intraoperative Fascial Traction device (with video)**

H. Niebuhr et. al., 2021: **Intraoperative Fascia Tension as an Alternative to Component Separation. A Prospective Observational Study**

OPEN ABDOMEN

Dohmen J, Weissinger D, Peter AST, Theodorou A, Kalff JC, Stoffels B, Lingohr P, von Websky M., 2024: **Evaluating a novel vertical traction device for early closure in open abdomen management: a consecutive case series**

Thomas Mones et al.. 2024: **Vertical Mesh-Mediated Fascial Traction and Negative Pressure Wound Therapy: A Case Series of Nine Patients in General and Vascular Surgery**

P. Nguyen, Ramana Balasubramaniam, 2024: **AbThera, Botox, and Fasciotens: A Trifecta in Open Abdomen Management**

Mavc, Z., Kunst, G., 2023: **Fasciotens®Abdomen system application for delayed primary fascial closure and observed physiological improvement of the patient**

Fung, S., Ashmawy, H., Krieglstein, C. et al., 2022: **Vertical traction device prevents abdominal wall retraction and facilitates early primary fascial closure of septic and non-septic open abdomen**

T. Halama, R. Nazzal, T. Nowroth, 2020: **Fasziendehnung zum Bauchverschluss nach perforiertem Bauchaaortenaneurysma**

A. Hees, F. Willeke, 2020: **Prevention of Fascial Retraction in the Open Abdomen with Novel Device**

Gombert, A., Eickhoff, R., Doukas, P. et al., 2020: **Vollständiger Bauchdeckenverschluss bei offenem Abdomen nach notfallmäßiger komplexer Aortenrekonstruktion bei „mid-aortic syndrome“ durch Anwendung von Fasciotens Abdomen® im Fall eines 16-jährigen Patienten**

Eickhoff, R. et al., 2019: **A new device to prevent fascial retraction in the open abdomen – proof of concept in vivo**

S. Fung et. al., 2019: **Fasciotens© Abdomen ICU: Novel Device Prevents Abdominal Wall Retraction and Facilitates Early Abdominal Wall Closure of Septic Open Abdomen**

PEDIATRIC

Ziegler, AM., Svoboda, D., Lücken-Darius, B. et al., 2024: **Use of a new vertical traction device for early traction-assisted staged closure of congenital abdominal wall defects: a prospective series of 16 patients**

Scan for all hernia publications:



Scan for all open abdomen publications:



Scan for pediatric publications:



www.fasciotens.com

fasciotens
ABDOMINAL WALL SOLUTIONS